

Identification of Generalised (AA) Amyloidosis in an Arabian Gazelle (*Gazella gazella* sp.)

R.I. Fox^{1*}, C.E. Payne-Johnson¹, S. Sanderson²

¹Department of Veterinary Pathology, University of Liverpool, Merseyside, England;

²North of England Zoological Society, Chester Zoo, Cheshire, England.

*Corresponding author: rfox@liverpool.ac.uk

KEYWORDS

Gazelle, Amyloid, AA Amyloidosis, Kidney.

INTRODUCTION

Amyloidosis has been previously documented in Dorcas and Mountain gazelles, most notably in a herd of Dorcas gazelles of the National Zoological Park in Washington⁸. The renal medulla was principally involved, leading to renal failure. In some cases there was more generalised involvement including the liver, spleen, adrenal glands and intestine. Studies have shown that this is of the reactive type (AA), which is believed to be derived from the acute phase protein SAA⁴. This case report identifies generalised AA amyloidosis in an Arabian gazelle in which there was glomerular and medullary deposition.

CASE HISTORY

A 5-years-old Arabian gazelle (*Gazella gazella* sp.) was submitted for necropsy. The animal had died after a 4-month history of diarrhoea and weight loss. Coccidial organisms had been isolated two months previously and subsequently treated with sulphonamide antimicrobials. Repeat faecal analysis one month later did not reveal any coccidia. Two successive complete blood counts and serum chemical analysis were performed. In the initial sample, serum urea nitrogen (109.24 mg/dl) was elevated (normal range: 8-43 mg/dl¹). Serum creatinine was within normal parameters. On necropsy the animal was severely emaciated and dehydrated. However, significant gross post-mortem lesions were not apparent. Renal capsules peeled easily from cortical surfaces. Both kidneys were slightly firm on palpation. Left and right kidneys weighed 30g and 32g respectively. Kidneys were red-tan. Cortical and medullary tissues were moderately congested but

otherwise unremarkable. No significant organisms were isolated from mucosal scrapes of the stomach, ileum and caecum. There was no evidence of protozoal enteritis on histology.

MATERIALS AND METHODS

Tissues collected at necropsy were fixed in 10% neutral buffered formalin, processed, embedded in paraffin, sectioned and stained with Haematoxylin and Eosin (HE). Selected sections of kidney, small and large intestine, spleen were stained with Sirius Red (SR) according to LLEWELLYN (1970) and also with Congo Red (CR) according to RIJSWIJK *et al.* (1979). Replicate sections of kidney, spleen and intestine were taken. In order to distinguish AA amyloid from other types, these were oxidised with potassium permanganate according to the method described by RIJSWIJK *et al.* (1979) and then stained using SR or CR.

HISTOPATHOLOGY

Both kidneys displayed extensive deposits of amorphous eosinophilic material within the glomeruli, medullary interstitium and blood vessel walls. The deposits stained positively with SR and CR and lost affinity for the stains after oxidation with potassium permanganate, confirming AA amyloid composition.

Within the cortex (Figure 1), amyloid deposits were present in distended glomeruli effacing capillaries and narrowing urinary spaces. Some glomeruli were atrophic. In the medulla (Figure 2), amyloid surrounded degenerate and atrophic medullary tubules and was arranged in broad bands. Hyaline casts were present within cortical and medullary tubule lumen. There were also mild diffuse lympho-

cytic accumulations within cortical interstitium. There was no evidence of papillary necrosis.

In the spleen (Figure 3), amyloid deposits involved blood vessel walls and the trabecular system. There were myriad siderophages within red pulp. All sections of small intestine (duodenum, jejunum and ileum) revealed moderate diffuse amyloid deposits within the submucosa and blood vessel walls of the submucosa and muscularis mucosa. All sections of the large intestine (colon and caecum) revealed similar amyloid deposits.

DISCUSSION

Approximately 95% of amyloid consists of fibril proteins, the remaining 5% being the P component and other glycoproteins⁴. The P component has structural homology to C-reactive protein, a well-known acute phase reactant. The serum P component has a high affinity for amyloid fibrils and it is thought that it is necessary for tissue deposition. Currently there are 15 distinct forms of amyloid proteins. Type AA is one of the three most common forms found in man². Others include AL (amyloid light chain) and A β . In reactive systemic amyloidosis (secondary), amyloid AA is derived from a larger precursor in the serum called SAA (serum amyloid-associated). This is an active-phase immunoregulant product of hepatocytes, in association with HDL3 (high density lipoprotein) subclass of lipoproteins. This is commonly produced in excess as a result of chronic antigenic stimulation⁹. The precise process by which amyloid is deposited in tissues is still not fully understood.

After initial examination of sections stained with HE, SR staining was used exclusively to identify the specific localisation of amyloid. SR stains amyloid material rose red whereas CR stains amyloid brick red. CR is a more capricious stain and commonly results in non-specific "background" staining, which can reduce morphologic clarity. With SR stain, unwanted background staining is less commonly encountered and so gives better contrast between affected and non-affected tissue. CR is, however, birefringent in polarised light and has fluorochromic properties which can, on occasions, be utilised to accentuate weak staining with SR³.

Comparative CR staining with SR preparations revealed similar amyloid distribution and the affinity of both stains to amyloid was negative when pre-treated with potassium permanganate, confirming type AA amyloid.

Interestingly, the distribution of amyloid in this case involves the glomeruli and not the cortical interstitium. In a previous study by RIDEOUT *et al.* (1989), renal medullary amyloidosis (RMA) was the

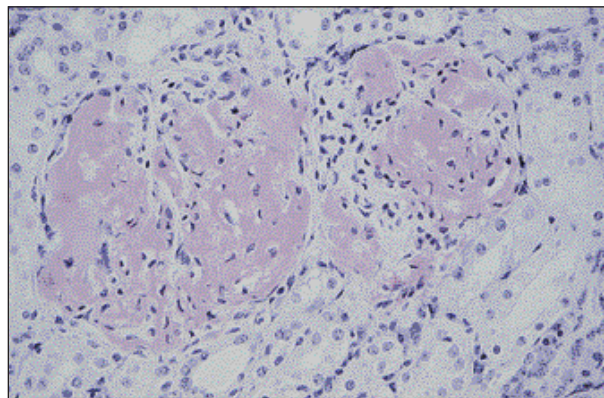


Figure 1: Glomerular amyloid deposits. Amyloid is confined to glomeruli and occasionally within vascular walls. Glomerular amyloid is capillary associated. (SR). Original magnification 400x.

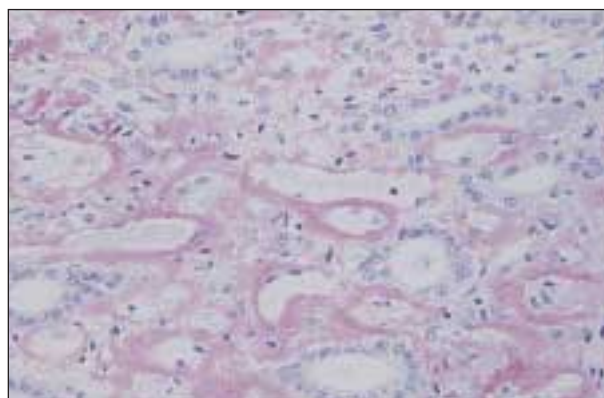


Figure 2: Medullary interstitial amyloid with multifocal tubular degeneration and atrophy. (SR). Original magnification 200x.

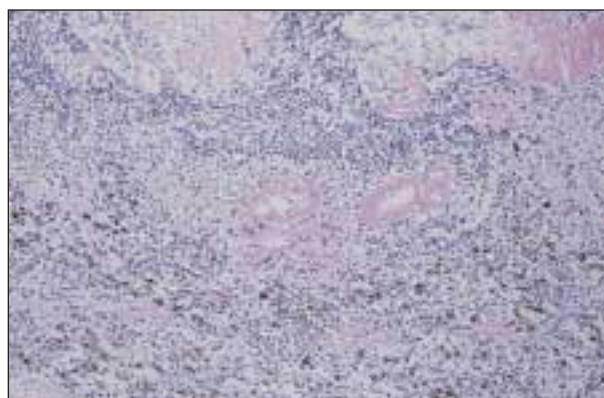


Figure 3: Splenic vascular intramural and intratrabeccular amyloid. Note myriad siderophages and scant amyloid within red pulp. (SR). Original magnification 200x.

primary pathological change in the kidneys of the Dorcas gazelles presented for necropsy without significant involvement of glomeruli. The Mountain gazelle reported by LINKE *et al.* (1986) displayed amyloid deposits within the glomeruli and tubular interstitium. However, the distribution of interstitial amyloid was not specified in this report.

There was no evidence of papillary necrosis in this case, which might be expected, due to ischemia caused by amyloid obstruction of renal vasculature⁶. Interstitial fibrosis was also not a feature.

The distribution of amyloid in this case closely resembles that reported in dairy cattle⁵, in which there are both glomerular and medullary amyloid deposits.

Previous studies of secondary amyloidosis in gazelles have shown no familial link and a large number of animals necropsied had concurrent chronic or recurrent inflammatory or infectious processes^{6,8}. In the studies carried out by RIDEOUT *et al.* (1989), *Arcanobacterium (Actinomyces) pyogenes* was isolated from nine of the seventeen gazelles necropsied. In another study of exotic Bovidae and cervidae¹⁰ *A. pyogenes* was isolated frequently from chronic or recurrent infections. This is comparable to humans who have concurrent diseases such as tuberculosis, chronic osteomyelitis or inflammatory bowel disease.

The gazelle in this study was unusual in the fact that it had no identifiable long-term chronic or recurrent infections. There was coccidial enteritis of one month's duration. There may have been a previous clinically unrecognised infection. The pattern of amyloid distribution differed from previously reported cases in Dorcas gazelles. The distribution of amyloid in this case involved the glomeruli as well as the renal medullary interstitium, but did not involve the cortical interstitium. As no underlying disease process could be determined in the Arabian gazelle, the amyloidosis was classified as idiopathic, type AA.

ACKNOWLEDGEMENTS

R. Fox's Pathology Residency was supported by The Home of Rest for Horses. The authors would

like to thank Mr A. Brandwood and his associates in histology for excellent technical assistance and Dr G. Wibbelt and Dr J. S. McKay for their help and contributions.

REFERENCES

1. BUSH M, SMITH EE, CUSTER RS, 1981: Hematology and serum chemistry values for captive Dorcas gazelles: variations with sex, age and health status. J Wildl Dis, 17, 135-43.
2. COTRAN RS, KUMAR V, COLLINS T, Amyloidosis p 251-257 in: COTRAN RS, KUMAR V, COLLINS T, 1999: Pathologic Basis of Disease, 6th ed. W. B. Saunders Company.
3. FRANCIS RJ, Amyloid p 155-175 in: BANCROFT J D, STEVENS A, 1990: Theory and Practice of Histological Techniques, 3rd Ed. Churchill Livingstone.
4. GRANT MAXIE M, The Urinary System p 447-537 in: JUBB KVF, KENNEDY PC, PALMER N, 1993: Pathology of Domestic Animals, 4th Ed. New York: academic Press, Inc.
5. JAKOB W, 1971: Spontaneous amyloidosis of mammals. Vet Pathol, 8, 292-306.
6. LINKE RP, HOL PR, GEISEL O, 1986: Immunohistochemical identification of generalized AA-amyloidosis in a mountain gazelle (*Gazella gazella*). Vet Pathol, 23, 63-67.
7. LEWELLYN BD, 1970: An improved SR method for amyloid. J Med Lab Technol, 27, 308-309.
8. RIDEOUT BA, MONTALI RJ, WALLACE RS, BUSH M, PHILLIPS LG, ANTONOVYCH TT, SABNIS SG, 1989: Renal medullary amyloidosis in Dorcas gazelles. Vet Pathol, 26, 129-35.
9. VAN RIJSWIJK MH, VAN HEUSDEN CW, 1979: The potassium permanganate method. A reliable method for differentiating amyloid AA from other forms of amyloid in routine laboratory practice. Am J Pathol, 97, 43-58.
10. ZULTY JC, MONTALI RJ, 1988: *Actinomyces pyogenes* infection in exotic Bovidae and Cervidae: 17 cases (1978-1986). J Zoo Anim Med, 19, 30-32.